

## RHEGMATOGENOUS RETINAL DETACHMENT IN HIGH MYOPIA

Priscilla Christina Natan<sup>1</sup>, Putu Budhiastra<sup>2</sup>, Ari Andayani<sup>3</sup>, Komang Putra Tridiyoga<sup>4</sup>

General Practitioner, Balimed Hospital Denpasar<sup>1</sup>, Bali Ophthalmologist, Balimed Hospital Denpasar<sup>2</sup>, Bali Ophthalmologist, Ramata Eye Hospital<sup>Denpasar3</sup>, Bali Ophthalmologist, Balimed Hospital Denpasar, Bali<sup>4</sup>  
[priscillanatan@gmail.com](mailto:priscillanatan@gmail.com)

---

### Abstrak (Indonesia)

Received: 20 Oktober  
2022

Revised : 25 Oktober 2022

Accepted: 30 Oktober 2022

**Latar Belakang:** Miopia tinggi berhubungan dengan pemanjangan bola mata, dan pemanjangan bola mata yang berlebihan dapat menyebabkan peregangan mekanis dan penipisan lapisan koroid dan epitel pigmen retina (RPE), sehingga menyebabkan berbagai perubahan degeneratif retina, salah satunya adalah ablasi retina. Ablasio retina adalah suatu kondisi ketika retina neurosensori terlepas dari RPE dengan miopia tinggi sebagai salah satu faktor risikonya.

**Tujuan:** Melaporkan kasus ablasio retina regmatogenosa dan robekan retina multipel pada pasien miopia tinggi. Melaporkan kasus ablasio retina regmatogenosa dan robekan retina multipel pada pasien miopia tinggi.

**Metode:** Seorang wanita berusia 45 tahun datang ke Rumah Sakit Balimed dengan pandangan kabur mendadak pada mata kiri, ketajaman penglihatan menghitung jari (3/60) dan riwayat miopia tinggi pada kedua mata. Mata kanan S-9.00 dan Mata kiri S-6.00. Pada pemeriksaan oftalmologi ditemukan ablasi retina dan robekan retina multiple pada mata kiri. Dia dirujuk ke Rumah Sakit Mata Ramata Denpasar, dan menjalani pars plana vitrectomy (PPV) dengan injeksi gas C3F8 intravitreal dan endolaser (EL) untuk robekan retina multipel pada mata kiri sekitar 2 minggu kemudian (12 September 2022). Satu bulan setelah vitrektomi, tekanan intraokular normal.

---

Operasi berhasil dilakukan dan pada kunjungan tindak lanjut tampak retina menempel dan terdapat peningkatan tajam penglihatan yaitu 6/38 pada mata kiri.

**Hasil:** Miopia tinggi merupakan salah satu faktor terbesar terjadinya ablasio retina. Penatalaksanaan ablasi retina bervariasi tergantung pada area ablasi, usia pasien, presentasi klinis dan temuan sistemik lainnya.

**Kesimpulan:** Ablasio retina regmatogenosa merupakan tipe ablasio retina yang paling sering terjadi yang terutama disebabkan oleh miopia tinggi. RD adalah keadaan ablasi neurosensori retina dari RPE dengan miopia tinggi sebagai faktor risiko. Penatalaksanaan RRD dapat mencakup scleral buckle atau Pars Plana Vitrectomy. Dalam kasus ini, dilaporkan bahwa RRD dengan pengobatan segera dengan PPV menghasilkan peningkatan ketajaman visual yang baik.

**Kata kunci:** *Ablasi Retina; Rhegmatogenous; Miopia Tinggi*

#### **Abstract (English)**

**Background:** *High myopia is associated with elongation of the eyeball, and excessive elongation of the eyeball can cause mechanical stretching and thinning of the choroid layer and retinal pigment epithelium (RPE), causing various degenerative changes of the retina, one of which is retinal detachment. Retinal detachment is a condition when the neurosensory retina detaches from the RPE with high myopia as a risk factor.*

**Objective:** *Reported a case of rhegmatogenous retinal detachment and multiple retinal tears in a high myopia patient. Reported a case of rhegmatogenous retinal detachment and multiple retinal tears in a high myopia patient.*

**Methods:** *A 45-year-old woman came to Balimed Hospital with sudden blurring of vision in her left*

---

---

eye, visual acuity on counting fingers (3/60) and a history of high myopia in both eyes. Right eye S-9.00 and left eye S-6.00. On ophthalmologic examination, retinal detachment and multiple retinal tears were found in the left eye. He was referred to Ramata Eye Hospital Denpasar, and underwent pars plana vitrectomy (PPV) with intravitreal injection of C3F8 gas and endolaser (EL) for multiple retinal tears in the left eye approximately 2 weeks later (12 September 2022). One month after vitrectomy, intraocular pressure was normal. The operation was successful and at the follow-up visit the retina was attached and there was an increase in visual acuity of 6/38 in the left eye.

**Results:** High myopia is one of the biggest factors for retinal detachment. Management of retinal detachment varies depending on the area of detachment, patient age, clinical presentation and other systemic findings.

**Conclusion:** Rhegmatogenous retinal detachment is the most common type of retinal detachment caused mainly by high myopia. RD is a state of retinal neurosensory detachment from RPE with high myopia as a risk factor. Management of RRD may include a scleral buckle or pars plana vitrectomy. In this case, it was reported that RRD with prompt treatment with PPV resulted in a good improvement in visual acuity.

**Keywords:** Retinal detachment; Rhegmatogenous; High Myopia

---

\*Correspondent Author : Priscilla Christina Natan  
Email : priscillanatan@gmail.com



## BACKGROUND

High myopia or pathological myopia is associated with globe elongation and refractive error of at least 6 diopters (D) and/or axial length of greater than 25.5 mm. The prevalence of high myopia varies considerably in different ethnic groups and has been estimated to be around 10% in Asian populations. Excessive axial elongation of the globe can cause mechanical stretching and thinning of the

choroid and retinal pigment epithelium (RPE) layers, resulting in various retinal degenerative changes, such as retinal detachment (Kreissig, 2005). Retinal detachment caused by high myopia can be repaired by pneumatic retinopexy, placement of a scleral buckle to hold the retina to the eye, or repaired by pars plana vitrectomy and replaced with silicone gel after the retina is reattached with laser. Although the success rate of reattachment of retina is much higher with the modern techniques of pars plana vitrectomy and internal tamponades, conventional scleral buckling is still considered to be a safe and effective technique in the primary management of uncomplicated rhegmatogenous retinal detachment (Khan, Jan, Karim, Iqbal, & Saeed, 2010).

## **RESEARCH METHODS**

A 45 years old woman came to the Balimed Hospital on August 30<sup>th</sup> 2022, with the chief complaint of sudden blurry vision on the left eye, with finger counting visual acuity and history of high myopia in both eyes. Right eye S-9.00 and Left eye S-6.00. On ophthalmological examination on August 30<sup>th</sup> 2022 found that the visual acuity 6/9.5 of the right eye and 3/60 on the left eye (Sung, Lee, Won, Lim, & Kim, 2020). Orthotropia eyeball position, no movement restriction in all directions. The intraocular pressure (IOP) was 11 mmHg and the left eye was 12 mmHg. Examination of the anterior segment of the right eye was within normal limits. An examination of the anterior segment of the left eye revealed cornea with a pigment iris, irregular pupil, posterior synechia, and slightly cloudy lens. On the posterior segment, there is a retinal detachment multiple retinal tears on the left eye (Henry, Covert, Han, Sanchez, & Bhatia, 2010).

The patient was diagnosed with rhegmatogenous retinal detachment (RRD)LE + high myopia both eyes (Tetsumoto et al., 2020). She was referred to Ramata Eye Hospital Denpasar, and underwent a pars plana vitrectomy (PPV) with intravitreal C3F8 gas injection and endolaser (EL) for multiple retinal tears on the left eye around 2 weeks later (September 12<sup>th</sup> 2022) (Hakin, Lavin, & Leaver, 1993).

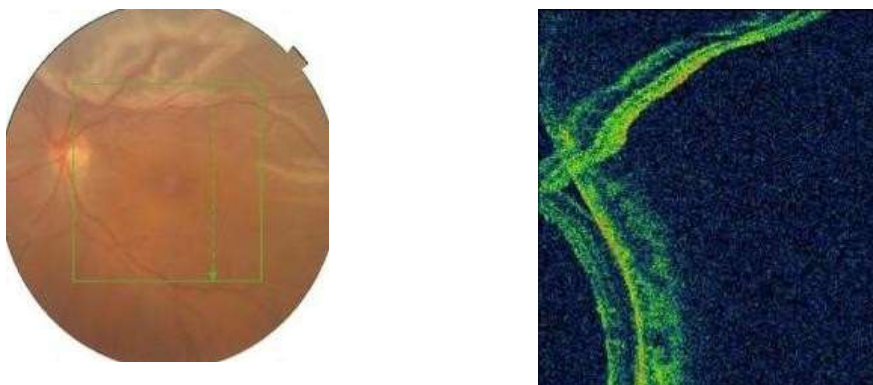


Figure 1. The results of Fundus Photo and Optical Coherence Tomography (OCT) on Left Eye on August 30<sup>th</sup> 2022 shows the rhegmatogenous retinal detachment on superior retina

One day after the operation on August 31<sup>st</sup> 2022, ophthalmological examination revealed IOP RE 11 LE 12. The anterior segment RE is within normal limit, cornea is clear, isocor pupil, and the lens is slightly cloudy, the posterior segment of the left eye has the retina completely attached. The patient received 2x500 mg ciprofloxacin tablets, levofloxacin eye drops 6 times/day LE, prednisolone acetate eye drops 6 times/day LE, and paracetamol tablets 3x500 mg orally (Hwang, 2012). One week postoperative follow up visit showed light perception on the right eye and hand movement on the left eye, IOP RE 12 and in RE 14 (Jackson, Donachie, & Johnston, 2016). Examination of anterior segment of right eye and left eye was still the same as day one postoperative. The patient was then advised to follow up visit two weeks later and received eye drop therapy of prednisolone acetate 5 times/day LE with weekly tapering off and levofloxacin 6 times/day LE (Soni, Hainsworth, & Almony, 2013). One month after the pars plana vitrectomy, the intraocular pressure is normal. The operation was successfully performed and on the follow up visit the retina appeared attached and there is an improvement of visual acuity is 6/38 on the left eye (Bourla, Bor, Axer-Siegel, Mimouni, & Weinberger, 2010).

## RESULTS AND DISCUSSION

People with high myopia are prone to retinal detachment. A detach retina needs immediate diagnosis and treatment to prevent vision loss (Park et al., 2015). Myopia is caused by an eyeball that's longer than normal. Because the eyeball is longer, it pulls on the retina and is prone to pulling a piece of retina off the back of the eye wall (Heussen et al., 2011). The retina is also thinner overall in myopic people and more prone to developing small holes or tears (Campo et al., 1999).

People with myopia -1 to -3 diopters have a risk four times as high as the general population of RD, while people whose refractive error is higher than -3 diopters have a tenfold risk. The risk of RD in high myopes (people with a -6.00 or higher diopter) is 5% per year. A study reported in the American Journal of Epidemiology suggests that 55% of all RDs are caused by myopia (Sharma, Grigoropoulos, & Williamson, 2004).

Retinal detachment is divided into two major groups, in the presence of traction and in the absence of traction. The most common type of retinal detachment is rhegmatogenous retinal detachment (RRD) which occurs due to the entry of fluid from the vitreous cavity into the potential space between the neurosensory retina and the retinal pigment epithelium (RPE) through full thickness breaks or holes (Alexander, Ang, Poulson, & Snead, 2008). The most common tear is a horseshoe tear that occurs in sites with large vitreoretinal adhesions, generally occurring at the posterior border of the vitreous base in the posterior vitreous detachment (PVD) (Chan, Lin, Nuthi, & Salib, 2008). The characteristics of RRD include the mobility disorder of the liquefied vitreous gel, the traction force that can cause a break in the retina, a retinal break that can be passed through the liquefied vitreous into the subretinal space. RRDs that occur posterior to the equator are a feature of RRD resulting from high myopia. Risk factors for RRD include high myopia, family history of RRD, history of contralateral eye tears or detachments, recent vitreous detachment, and trauma. The patient in this case report had RRD with risk factors of high myopia, the patient had a history of correction of vision with S-9.00 RE, and -6.00 LE, but the patient was using S-6.00 on both eyes for her convenience (Thompson, 1989).

Rhegmatogenous retinal detachment (RRD) is a severe vision-threatening condition (Wong & Thompson, 1988). Current treatment modalities for RRD include pars plana vitrectomy (PPV) and scleral buckling. Notably, PPV with a wide-angle viewing system has been gaining popularity as the first-line therapy, primarily because of its low invasiveness. Self-sealing small incisions lead to less surgical trauma, postoperative inflammation, and postoperative astigmatism, resulting in better postoperative comfort for patients and an earlier visual recovery.<sup>10-22</sup> However, disadvantages of PPV for RRD include postoperative visual disturbance and limitations in day-to-day activities for an extended period, due to gas tamponade within the vitreous cavity.<sup>23</sup> Typically, sulfur hexafluoride (SF<sub>6</sub>), octafluoropropane (C<sub>3</sub>F<sub>8</sub>), and room air are used as postoperative tamponade materials to seal causal retinal breaks; 20% SF<sub>6</sub> lasts for ~2 weeks,<sup>23-25</sup> while 13% C<sub>3</sub>F<sub>8</sub> lasts for ~2 months<sup>23,24</sup> in the vitreous cavity. In comparison to these materials, room air has a shorter absorption time (Fineberg et al., 1975). Therefore, room air may be useful for reducing the disadvantages of PPV listed

above. In addition, tamponade with room air has a lower probability of increased intraocular pressure and a reduced possibility of concurrent cataracts compared to long-acting gases (LAGs), such as SF<sub>6</sub> and C<sub>3</sub>F<sub>8</sub> (Ji, Rong, & Lu, 2018).

Pneumatic retinopexy and scleral buckle are the initial treatment options for patients with localized one-quadrant detachment (Esteban, Mateo, Casas, Lara, & Ascaso, 2021). Young patients with a hole in the anterior are advised to undergo a scleral buckle procedure.<sup>3</sup> PPV is indicated in patients with a large, bullous retinal detachment, and in elderly patients with a liquefied vitreous. Retinal detachments with multiple quadrant breaks, or patients with invisible breaks, or pseudophakic patients are also good candidates for PPV. Vitreous liquefaction occurs naturally due to aging, but can occur more rapidly in high myopia, surgical or non-surgical trauma, and in intraocular inflammation. In this patient, PPV was performed considering that vitreous liquefaction had occurred due to high myopia and the presence of intraocular inflammation (Rey et al., 2018).

Pars plana vitrectomy (PPV) is a commonly employed technique in vitreoretinal surgery that enables access to the posterior segment for treating conditions such as retinal detachments, vitreous hemorrhage, endophthalmitis, and macular holes in a controlled, closed system. The procedure derives its name from the fact that vitreous is removed (i.e. vitreous + ectomy = removal of vitreous) and the instruments are introduced into the eye through the pars plana.

Patients with RRD may present with floaters, photopsia, and/or a “curtain” defect that obscures part of the visual field. Visual acuity (VA) ranges from excellent to poor, depending on whether the macula is still attached. In patients with macula-off RRD, vision usually is decreased. If the area of detachment is large, an afferent pupillary defect may be present. Intraocular pressure (IOP) can be low or high. Low IOP results from increased outflow of intraocular fluid through the subretinal space and peripapillary connective tissue, particularly if the optic disc border is involved. High IOP may occur with chronic RRD, in which photoreceptor outer segments transgress into the anterior chamber and trabecular meshwork, impeding aqueous outflow.<sup>7,8</sup>

Up to 90 % of retinal detachments can be successfully re-attached. According to Prevent Blindness America, 40% of people after retinal re-attachment have excellent vision; the other 60% will have some vision loss. 85% percent of cases will be successfully treated with one operation with the remaining 15 percent requiring 2 or more operations. After treatment patients gradually regain their vision over a period of a few weeks, although the visual acuity may not be as good as it was prior to the detachment, particularly if the

macula was involved in the area of the detachment. However, if left untreated, total blindness could occur in a matter of days. <sup>5,6</sup>

One of the most serious complications often occurs after pars vitrectomy surgery plana is cataract, where in 12.5%-80% of post vitrectomy patients have cataracts within 48 months. The most common type of cataracts are posterior subcapsular cataract and nuclear sclerotic cataract. Pathophysiology of cataract formation after vitrectomy still not known for certain, however several factors are believed to play a role in post-cataract formation after vitrectomy, including the age of the patient, history of nuclear sclerosis, duration of action vitrectomy, composition of infusion fluids drained into the vitreous cavity or cannula, diabetic retinopathy, extensive damage occurs while the action is taking place, injury to the lens during vitrectomy in progress, light toxicity, disposal and vitreous gel replacement, and use of gas or silicone oil intraocular. <sup>26-28</sup>

## CONCLUSION

Rhegmatogenous retinal detachment is a the most common type of retinal detachment which mainly caused by high myopia. RD is a state of retinal neurosensory detachment from RPE with high myopia as a risk factor. Management of RRD can include scleral buckle or Pars Plana Vitrectomy. In this case, it is reported that RRD with immediate treatment with PPV produce a favorable visual acuity improvement.

## REFERENCES

- Alexander, P., Ang, A., Poulson, A., & Snead, M. P. (2008). Scleral buckling combined with vitrectomy for the management of rhegmatogenous retinal detachment associated with inferior retinal breaks. *Eye*, 22(2), 200–203.
- Bourla, Dan H., Bor, Elite, Axer-Siegel, Ruth, Mimouni, Karin, & Weinberger, Dov. (2010). Outcomes and complications of rhegmatogenous retinal detachment repair with selective sutureless 25-gauge pars plana vitrectomy. *American Journal of Ophthalmology*, 149(4), 630–634.
- Campo, Randy V, Sipperley, Jack O., Sneed, Scott R., Park, Donald W., Dugel, Pravin U., Jacobsen, Jaclin, & Flindall, Richard J. (1999). Pars plana vitrectomy without scleral buckle for pseudophakic retinal detachments. *Ophthalmology*, 106(9), 1811–1816.
- Chan, Clement K., Lin, Steven G., Nuthi, Asha S. D., & Salib, David M. (2008). Pneumatic retinopexy for the repair of retinal detachments: a comprehensive review (1986–2007). *Survey of Ophthalmology*, 53(5), 443–478.
- Esteban, Olivia, Mateo, Javier, Casas, Paula, Lara, Javier, & Ascaso, Javier. (2021). Cataract Surgery in Post-Vitrectomized Eyes. In *Current Cataract Surgical Techniques* (p. 37). IntechOpen.
- Fineberg, Edward, Machemer, Robert, Sullivan, Paul, Norton, E. W., Hamasaki, Duco, & Anderson, Douglas. (1975). Sulfur hexafluoride in owl monkey vitreous cavity. *American Journal of Ophthalmology*, 79(1), 67–76.
- Hakin, Kim N., Lavin, Michael J., & Leaver, Peter K. (1993). Primary vitrectomy for rhegmatogenous retinal detachment. *Graefe's Archive for Clinical and*

*Experimental Ophthalmology*, 231(6), 344–346.

- Henry, C. R., Covert, D. J., Han, D. P., Sanchez, C. R., & Bhatia, S. K. (2010). Risk Factors for Rhegmatogenous Retinal Detachment Following Pars Plana Vitrectomy for Epiretinal Membrane and Macular Hole. *Investigative Ophthalmology & Visual Science*, 51(13), 6063.
- Heussen, Nicole, Feltgen, Nicolas, Walter, Peter, Hoerauf, Hans, Hilgers, Ralf Dieter, & Heimann, Heinrich. (2011). Scleral buckling versus primary vitrectomy in rhegmatogenous retinal detachment study (SPR Study): predictive factors for functional outcome. Study report no. 6. *Graefe's Archive for Clinical and Experimental Ophthalmology*, 249(8), 1129–1136.
- Hwang, John C. (2012). Regional practice patterns for retinal detachment repair in the United States. *American Journal of Ophthalmology*, 153(6), 1125–1128.
- Jackson, Timothy L., Donachie, Paul H. J., & Johnston, Robert L. (2016). Electronic medical record database study of vitrectomy and observation for vitreomacular traction. *Retina*, 36(10), 1897–1905.
- Ji, Yinghong, Rong, Xianfang, & Lu, Yi. (2018). Metabolic characterization of human aqueous humor in the cataract progression after pars plana vitrectomy. *BMC Ophthalmology*, 18(1), 1–8.
- Khan, Muhammad Tariq, Jan, Sanaullah, Karim, Samina, Iqbal, Sophia, & Saeed, Nasir. (2010). Outcome of scleral buckling procedures for primary rhegmatogenous retinal detachment. *Trauma*, 16, 28–57.
- Kreissig, Ingrid. (2005). *Primary retinal detachment*. Springer.
- Park, Sung Who, Kwon, Han Jo, Kim, Ho Yun, Byon, Ik Soo, Lee, Ji Eun, & Oum, Bo Sup. (2015). Comparison of scleral buckling and vitrectomy using wide angle viewing system for rhegmatogenous retinal detachment in patients older than 35 years. *BMC Ophthalmology*, 15(1), 1–6.
- Rey, Amanda, Jürgens, Ignasi, Maseras, Xavier, Dyrda, Agnieszka, Pera, Patricia, & Morilla, Antonio. (2018). Visual outcome and complications of cataract extraction after pars plana vitrectomy. *Clinical Ophthalmology (Auckland, NZ)*, 12, 989.
- Sharma, A., Grigoropoulos, V., & Williamson, T. H. (2004). Management of primary rhegmatogenous retinal detachment with inferior breaks. *British Journal of Ophthalmology*, 88(11), 1372–1375.
- Soni, Chetan, Hainsworth, Dean P., & Almony, Arghavan. (2013). Surgical management of rhegmatogenous retinal detachment: a meta-analysis of randomized controlled trials. *Ophthalmology*, 120(7), 1440–1447.
- Sung, Jae Yun, Lee, Min Woo, Won, Yeo Kyoung, Lim, Hyung Bin, & Kim, Jung Yeul. (2020). Clinical characteristics and prognosis of Total Rhegmatogenous retinal detachment: a matched case-control study. *BMC Ophthalmology*, 20(1), 1–6.
- Tetsumoto, Akira, Imai, Hisanori, Hayashida, Mayuka, Otsuka, Keiko, Matsumiya, Wataru, Miki, Akiko, & Nakamura, Makoto. (2020). The comparison of the surgical outcome of 27-gauge pars plana vitrectomy for primary rhegmatogenous retinal detachment between air and SF6 gas tamponade. *Eye*, 34(2), 299–306.
- Thompson, John T. (1989). Kinetics of intraocular gases: disappearance of air, sulfur hexafluoride, and perfluoropropane after pars plana vitrectomy. *Archives of Ophthalmology*, 107(5), 687–691.
- Wong, Raymond F., & Thompson, John T. (1988). Prediction of the kinetics of disappearance of sulfur hexafluoride and perfluoropropane intraocular gas bubbles. *Ophthalmology*, 95(5), 609–613.



© 2021 by the authors. Submitted for possible open access publication under the terms and conditions of the Creative Commons Attribution (CC BY SA) license (<https://creativecommons.org/licenses/by-sa/4.0/>).