

ANALYSIS OF DIFFERENCES IN CYSTIC OVARIAN NEOPLASM VOLUME ON ABDOMEN-PELVIS MRI WITH MANUAL MEASUREMENT TECHNIQUE (LINEAR MEASUREMENT) AND ACTIVE CONTOUR LAPLACIAN OF GAUSSIAN (LOG) TECHNIQUE

Hafsi Afrizun Khatamsi^{1*}, Sugiyanto^{2**}, Tri Asih Budiati^{3***}

^{1,2} Semarang Health Polytechnic of Ministry of Health

³ Jakarta Pertamina Central Hospital

* hafsi.afrizun@gmail.com

ABSTRACT

MRI image evaluation of cystic ovarian neoplasms was done manually and is generally carried out by Radiologists using a manual technique called linear measurement. This technique has some weaknesses, including being considered a rough calculation estimate because measurements are made on only one largest slice and are vulnerable to subjectivity factors. This research applied a digital image processing program based on Matlab using a segmentation process and active contour Laplacian of Gaussian (LoG) in the measurement and calculation of the volume of cystic ovarian neoplasms. Analyze the differences in measurement results and find out which technique is better in the calculation of cystic ovarian neoplasm volume between techniques of linear measurement and techniques of active contour Laplacian of Gaussian (LoG). The research was done with 32 images of abdominal-pelvic MRI images with clinical cystic ovarian neoplasms, and measurements and calculations of the volume of cystic ovarian neoplasms were carried out using the technique linear measurement and active contour Laplacian of Gaussian (LoG). Measurement and calculation are done by Radiologists as an observer with data analysis using statistical processing. Analysis of MRI images of abdominal-pelvic MRI images with clinical cystic ovarian neoplasms using linear measurement and active contour Laplacian of Gaussian (LoG) techniques showed a difference with a p-value of 0.004 ($p < 0.05$). The results of measurements using the active contour laplacian of the Gaussian technique are better than the linear measurement, as indicated by the higher mean rank of the active contour laplacian of Gaussian, which was 17.50 (higher than the linear measurement value of 13.50).

Keywords: Abdominal-Pelvic MRI, Contrast-Enhanced T1W Fat saturated, Active Contour Laplacian of Gaussian (LoG)

This article is licensed under [CC BY-SA 4.0](https://creativecommons.org/licenses/by-sa/4.0/) 

INTRODUCTION

The ovaries are female genital organs that have a very important function and role in women's reproductive health, such as the place where egg cells develop, producing the hormones estrogen and progesterone in women (Wardiyah et al., 2022). These functions and roles can be disrupted by health problems that arise in the reproductive organs, especially the ovaries. One of the problems or disorders that occur in the ovaries is cystic ovarian neoplasm.

Neoplasms are abnormal cell growths that are found and develop in the uterus (womb), ovaries, fallopian tubes, and/or other organs in the pelvis (Yashinta Aqmalia, 2018). The medical term neoplasm is often referred to as tumor (Syakrani et al., 2018). A tumor is defined as "swelling" or a swelling or abnormal growth in the body (Soebagjo D, 2017). Cystic ovarian neoplasm also known as ovarian cyst is a tumor that develops in the ovaries (ovaries), small or large, cystic, semi-solid or solid, and/or mixed, benign or malignant that grows in the ovaries (Kadar & Amaliyyah, 2021). The World Health Organization (WHO) classifies neoplasms into four main categories, namely: benign neoplasm, in situ neoplasm, malignant neoplasm, and neoplasm of uncertain. A benign neoplasm is also commonly called a benign tumor, which is

a status when tumor cells cannot spread to other tissues. In situ neoplasm is a status where tumor cells have not spread to other tissues, but the possibility of spreading is very high. Malignant neoplasm or malignant tumor is a status when tumor cells have spread to other tissues, or what is usually called cancer. Meanwhile, neoplasm of uncertain is a tumor classification when there is doubt about whether the tumor is benign or malignant (Syakrani et al., 2018).

According to Globocan (2018), the prevalence of cystic ovarian neoplasms reached 295,414 women worldwide. In Indonesia, 13,310 cystic ovarian neoplasms were recorded in 2018 and 7,842 of them were declared dead (Khoiria et al., 2020). The incidence of death in sufferers of cystic ovarian neoplasms is due to some cases developing aggressive commonly known as ovarian cancer but being detected slowly (Tanjung, 2021). Ovarian cancer is often referred to as the silent killer because 60-70% of patients come to health services at an advanced stage, where the disease is initially asymptomatic and only manifests as complaints when metastases have occurred (Kurniasari et al., 2019).

Aggressive neoplasms that fall into the category of malignant tumors (cancer) can be treated in the form of a hysterectomy or surgical removal of the uterus, but this is not the main and only choice because it is also weighed based on the stage, the extent of spread and the patient's overall health condition. Apart from surgery, other treatments can include chemotherapy, radiotherapy, and a combination of both. The type and volume of ovarian neoplasms must be identified early for early detection so that it is useful to assist in making appropriate medical decisions as well as determining the best steps for healing and stopping tumor development.

Radiologists identify cases of cystic ovarian neoplasms by analyzing MRI images stored in DICOM (Digital Imaging Communication in Medicine) format and then measuring them using a simple and widely used manual measurement technique, called linear measurement. Measurements from the linear measurement technique in the MRI modality can be done quickly and do not require special expertise, however, calculating the volume and size of cystic ovarian neoplasms is a rough estimate so it does not represent the actual results of cystic ovarian neoplasm calculations, the results can also vary depending on the area of the section selected (Sreenivasan et al., 2016) (Westbrook & Talbot, 2019). Because measurements are still carried out manually, the possibility of a radiologist making a diagnosis error is greater, especially in determining the size and location of the tumor. Another thing that is a challenge in diagnosis is that the pelvic structure with a variety of anatomies with relatively the same gray level range will further complicate the identification process (Chakraborty et al., 2017). Subjective factors such as fatigue and inefficient time in evaluating manual techniques by radiologists are also problems, so tools are needed that can make image processing easier, especially in measuring the volume and size of cysts more quickly and accurately (Roy & Bandyopadhyay, 2012).

The scientific community has developed various image-processing techniques through staged tumor segmentation and classification. The benefits can help paramedics and patients predict tumors quickly, and accurately at an affordable cost. Segmentation is a process of partitioning an image into groups of identical pixels with certain characteristics. The result is a separation of the image into connected areas. Segmentation relates to dividing images into meaningful regions (Bangare et al., 2015), as well as being the best filter to separate abnormal areas from normal areas in MRI images which play an important role in helping diagnosis and treatment planning (Chakraborty et al., 2017). One segmentation technique that can be used to

obtain information and estimate the clinical area of a cystic ovarian neoplasm to be an area of interest is known as the active contour technique (Bangare et al., 2015).

Active Contour is a segmentation technique that utilizes a closed curve model that is capable of moving wider or narrower, which is sensitive and adaptive to detect object boundaries (Diah Priyawati, Indah Soesanti, 2015). The active contour technique aims to differentiate images well, but in the process, in areas with complex anatomy, leakage often occurs in the area of interest. So it can reduce accuracy in the segmentation process and make segmentation results inaccurate (Chakraborty et al., 2017). The application of active contour Laplacian of Gaussian (LoG) segmentation is one additional method to overcome the problem of active contour leakage. Laplacian of Gaussian (LOG) can smooth homogeneous areas and increase object edge information to make it clearer (Biswas & Hazra, 2020) (Abdulbaqi et al., 2015). So the combination of active contour and Laplacian of Gaussian (LOG) is considered appropriate, apart from overcoming leaks in the area of interest, it also increases the success of segmentation to be much better with accurate results on complex MRI images. The application of the active contour Laplacian of Gaussian (LoG) segmentation technique has great potential in clinical treatment by freeing radiologists from the burden of manual labeling and measurements (Diah Priyawati, Indah Soesanti, 2015).

In this study, a digital image processing program is proposed to calculate the volume of cystic ovarian neoplasms using the active contour Laplacian of Gaussian (LoG) segmentation process. Considering that there is no software as a complement to the MRI modality that radiologists can use to calculate the volume of cystic ovarian neoplasms.

METHOD

This type of research is quasi-experimental using a Posttest Only Without a Control Group Design. This study aims to determine whether there are differences in the results of measuring the volume of cystic ovarian neoplasms between the linear measurement technique and active contour Laplacian of the Gaussian technique (post-test). The research was carried out on a Siemens 1.5 Tesla MRI modality using 32 samples, and images from abdominal-pelvic MRI examinations with clinical cystic ovarian neoplasms, at Hermina Bekasi Hospital. Measurements were carried out by a radiologist as an observer on the abdominal-pelvic MRI image using a linear measurement technique through axial and sagittal cuts, then the results were compared with the active contour Laplacian of Gaussian (LoG) technique.

Analysis of data from measurements of cystic ovarian neoplasms between linear measurement techniques and active contour Laplacian of Gaussian (LoG) was then carried out with statistical tests. Calculation of the results of measurements of cystic ovarian neoplasms produced between the two techniques was tested for data normality using Shapiro-Wilk because the amount of data was less than 50. Bivariate data analysis, if the data was normally distributed (p value > 0.05), then the Paired T-test statistical test was carried out, and if the data was not normally distributed (p -value < 0.05), the Wilcoxon statistical test was carried out.

RESULTS AND DISCUSSION

In the technique of measuring and calculating cystic ovarian neoplasms using linear measurement techniques, they are measured on a workstation using Syngo software made by Siemens on a Siemens 1.5 Tesla MRI modality. Measurements and calculations were carried

out on MRI images with axial cuts on the T1 Fat saturated + contrast pulse sequence and sagittal cuts on the T1 Fat saturated + contrast pulse sequence because with this pulse sequence cystic ovarian neoplasms can be seen to be further enhanced by the introduction of contrast media which is injected intravenously.

Measurements and calculations of ovarian neoplasms using linear measurement techniques on a 1.5 Tesla Siemens MRI were obtained using the Ellipsoid equation to calculate volume-based diameter (V), Dcc=cranio-caudal diameter; Dl=lateral diameter; Dap=antero-posterior diameter (Jung & Kim, 2012).

$$V = \frac{(Dcc \times Dl \times Dap \times \pi)}{6}$$

The following are the results of measurements and calculations of cystic ovarian neoplasms using linear measurement techniques and active contour Laplacian of Gaussian (LoG) segmentation on a Siemens 1.5 Tesla MRI aircraft.

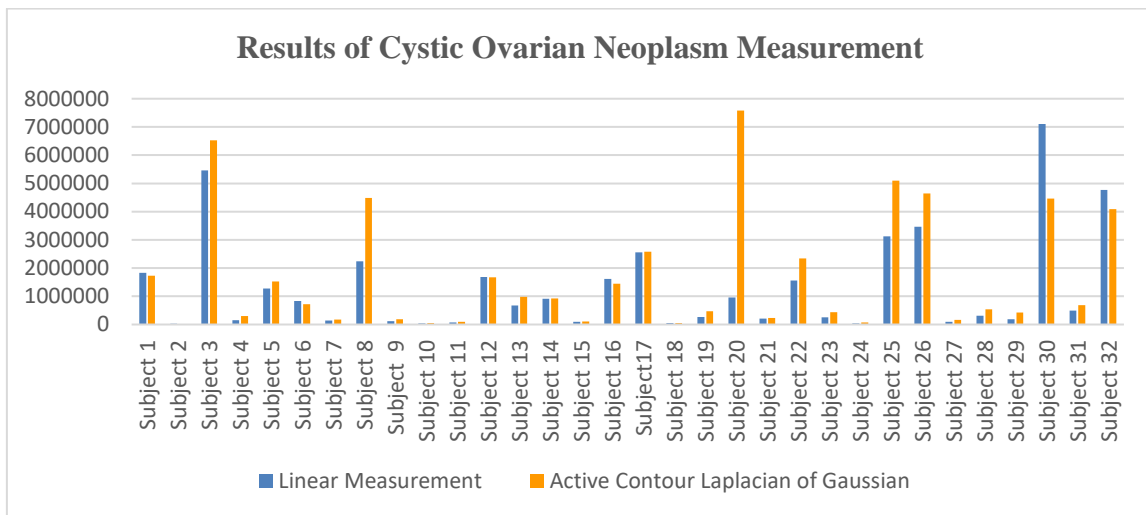


Figure 1. Results of measurements of cystic ovarian neoplasm

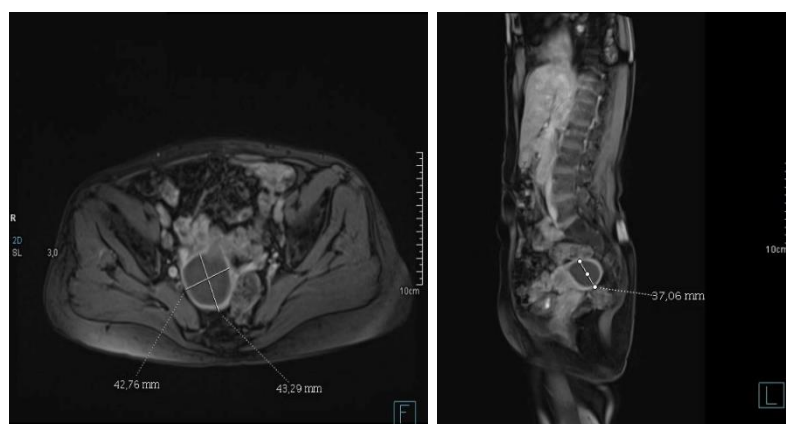


Figure 1. Results of measurements of cystic ovarian neoplasms using manual linear measurement techniques (a) axial section (b) sagittal section

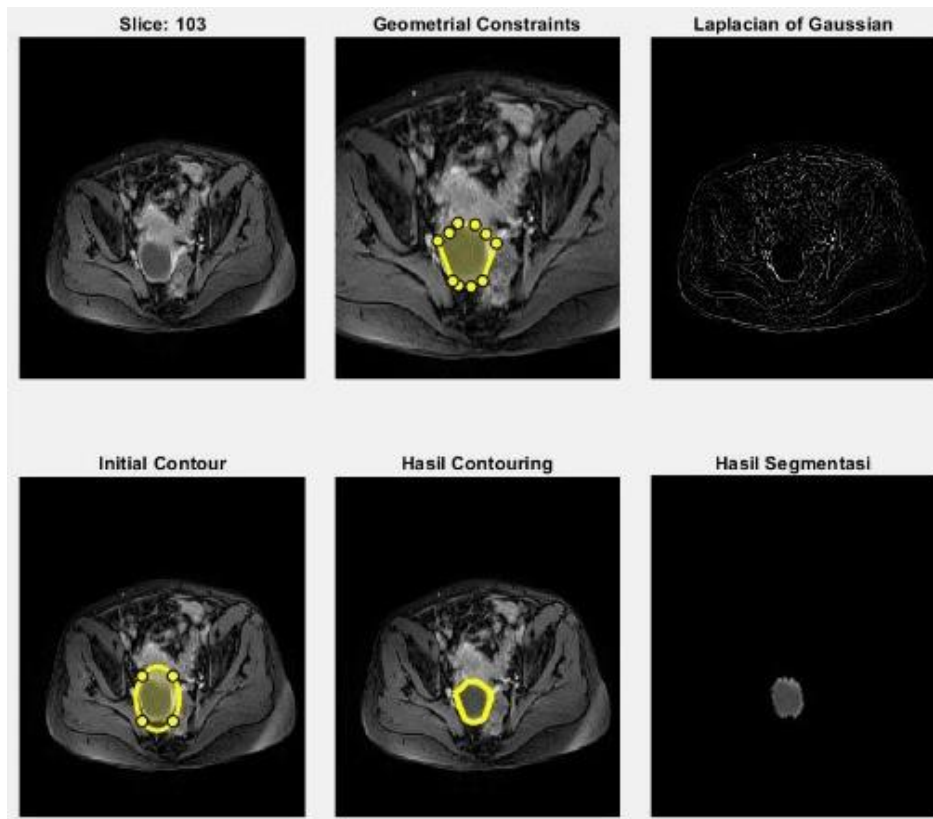


Figure 2. Results of measurements of cystic ovarian neoplasms using the active contour Laplacian of Gaussian (LoG) segmentation technique

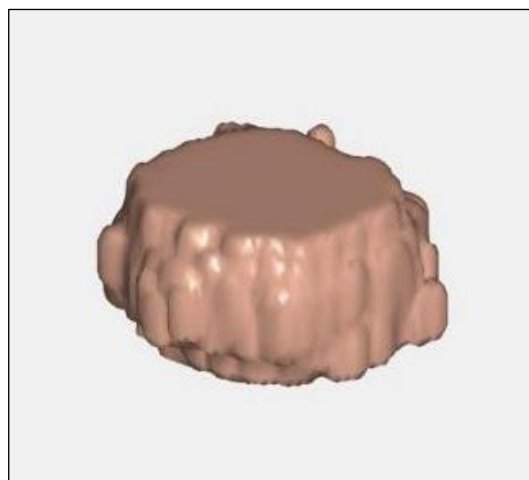


Figure 3. 3D visualization results using the active contour Laplacian of Gaussian (LoG) segmentation technique

Data Normality Test Results

Table 1. Normality Test Results for Measurement Data using linear measurement techniques and active contour Laplacian of Gaussian (LoG) techniques

No	Measurement technique	Significance (p-value)
1	Linear Measurement	0.000
2	Active Contour Laplacian of Gaussian	0.000

The results of the normality test of the data measured by the linear measurement technique and the active contour Laplacian of Gaussian (LoG) technique obtained a p-value <0.05, so it can be said that the data is not normally distributed, then the Wilcoxon non-parametric test can be carried out to determine whether there are differences in the volume measured by the linear measurement technique and the active contour Laplacian of Gaussian (LoG) technique.

Volume Difference Test Results

Table 2. Results of the Wilcoxon Test Analysis for measuring the volume of cystic ovarian neoplasms using the linear measurement technique and the active contour Laplacian of Gaussian (LoG) technique.

No	Measurement technique	Significance (p-value)	Meaning
1	Linear Measurement		There's a difference
2	Active Contour Laplacian of Gaussian	0.004	

The results of the Wilcoxon non-parametric statistical test above state that the p-value between the linear measurement technique compared to the active contour Laplacian of Gaussian (LoG) technique has a p-value of 0.004 (p<0.005). This states that there is a difference between volume measurements using linear measurement techniques and active contour Laplacian of Gaussian (LoG).

Better Engineering Test Results

Table 3. Mean Rank Results of the Wilcoxon Statistical Test measuring the volume of cystic ovarian neoplasms using the linear measurement technique and the active contour Laplacian of Gaussian (LoG) technique

No	Measurement technique	Mean Rank
1	Linear Measurement	13.50
2	Active Contour Laplacian of Gaussian	17.50

The mean rank results of the Wilcoxon test above show that the results of measuring the volume of cystic ovarian neoplasms using the active contour Laplacian of Gaussian (LoG)

technique have a higher mean rank value with a value of 17.50 compared to the linear measurement technique which has a mean rank value of 13.50.

Differences in the results of measurements and calculations of cystic ovarian neoplasms using manual linear measurement techniques compared with active contour Laplacian of Gaussian (LoG)

Based on the results of the Wilcoxon non-parametric statistical test, it was stated that there were differences in the results of measurements and calculations of cystic ovarian neoplasms between the linear measurement technique compared to the active contour Laplacian of Gaussian (LoG) segmentation technique with a significance value (p-value) < 0.05. The differences in results and calculation measurements for cystic ovarian neoplasms in the two techniques are because the measurements and calculations have different stages and measurement methods. In the manual linear measurement technique, measurements and calculations are carried out only on one slice, which according to the radiologist visualizes the size of the cystic ovarian neoplasm with the largest size, because it is considered to contain information that represents the size of the cystic ovarian neoplasm. The result is a value of $p \times l \times t$ or $D_{cc} \times D_l \times D_{ap}$ and then multiplied by the constant $\pi/6$ or 0.52 to obtain the total volume of cystic ovarian neoplasm. In this step, the measurement and calculation of cystic ovarian neoplasms can be subjective, according to Roy's research (2012), which revealed that subjective factors are the main problem or enemy that can influence radiologist evaluations using manual techniques because fatigue and uncontrolled time factors affect the accuracy of an evaluation. MRI images (Roy & Bandyopadhyay, 2012). Other research, namely Mbuyamba (2017), revealed that the subjectivity of visual perception can influence manual measurements by radiologists, especially when faced with a large MRI image database (Ilunga–Mbuyamba et al., 2017).

Several MRI examination results that visualize cystic ovarian neoplasms are heterogeneous with large sizes containing solid masses, pus, and blood and/or mixed. The presence of expansion with very large volume measurement results also indicates that the patient's prognosis is not good.

There are differences in measurement results in several subjects, showing that the results of linear measurements are greater than the results of active contour Laplacian of Gaussian (LoG) measurements or vice versa, namely the results of active contour Laplacian of Gaussian (LoG) segmentation measurements are greater than linear measurements. This happens because the linear measurement technique uses the basic measurement formula of an ellipsoid which adopts the equation of the ellipse formula which is derived from the basic definition and shape of the ellipse itself (Exhibit et al., 2014). An ellipse is the locus of a point where the sum of the distances from two points is constant. Suppose it is P (x, y), the focus is F and F'. Then the condition is $PF + PF' = 2a$. This is then applied to the linear measurement technique where the shape of the cystic ovarian neoplasm is assumed to be that the shape of the tumor or cystic ovarian neoplasm is an elliptical or round/spherical shape whose volume can be calculated. Meanwhile, active contour Laplacian of Gaussian (LoG) is a measurement based on the understanding that the overall volume is obtained if segmentation has been carried out on each slice which contains clinical information about cystic ovarian neoplasms. The segmentation

results for each slice are then interpreted in 3D visualization so that the actual shape and surface of the tumor can be seen.

A better technique for producing volume measurements of cystic ovarian neoplasms using manual linear measurement techniques compared to active contour Laplacian of Gaussian (LoG)

The mean rank value for measuring and calculating the volume of cystic ovarian neoplasms using the linear measurement technique is 13.50, while the mean rank value for measuring and calculating the volume of cystic ovarian neoplasms using the active contour Laplacian of Gaussian (LoG) technique is 17.50. This shows that the active contour laplacian of the Gaussian (LoG) technique has a higher mean rank than the linear measurement technique, meaning that the active contour laplacian of the Gaussian (LoG) technique is better at producing measurements and calculations of the volume of cystic ovarian neoplasms. This is to research by Maizza (2021), that active contour can classify images with high accuracy in producing volume measurements when compared with a simple technique using the ellipsoid formula (Putri et al., 2021). A similar thing was also expressed in Keyan's (2016) research where active contour combined with Laplacian of Gaussian can make the energy function smooth homogeneous regions and increase edge information, thereby providing optimal segmentation results with higher segmentation accuracy and efficiency (Ding et al., 2017).

Active contour Laplacian of Gaussian (LoG) produces excellent volume measurements of cystic ovarian neoplasms. The combination of the two complements each other and becomes a close part of the relationship to increase measurement accuracy. In their application to measuring the volume of cystic ovarian neoplasms, both have limitations that are filled with each other, namely active contour is susceptible to leakage in images that have relatively the same density, especially in clinical cystic ovarian neoplasms because they are located in the pelvis close to other anatomical organs so the density is relatively the same and difficult to differentiate, but has advantages in segmenting an area of interest because the process has an initiation masking stage where a Radiologist has direct involvement in being able to control and provide a pattern of signs of the clinical area of interest as initial information, the basis of the clinical characteristics of concern. While the Laplacian of Gaussian has the limitation of not having a Radiologist stage to mark patterns in clinical areas or areas of interest. Even though this is important to increase the success of segmentation, resulting in inaccurate volume measurements, it has the advantage of being able to act as a filter to improve an image that originally had blurry boundaries into a homogeneous image with sharper edges. So the application of a combination of both, namely active contour Laplacian of Gaussian, in this study is considered necessary to produce segmentation with high sensitivity, especially in areas with complex anatomy such as the pelvis.

In several subjects, the phenomenon of differences in the results of calculations of the volume of cystic ovarian neoplasms was found to be very extreme between the linear measurement and active contour Laplacian of Gaussian (LoG) measurement techniques. It was shown that 2 subjects showed extreme differences with the linear measurement results which had greater measurement results compared to the active contour Laplacian of Gaussian (LoG), this occurred in subjects with cystic ovarian neoplasms which had a tendency to malignancy (malignant) characterized by edge surfaces patchy, containing one or more complex mixtures

such as solid masses, hemorrhagic components, and septations. This is in line with research conducted by Hafidz (2020) which revealed that malignant ovarian tumors have cystic, mixed, solid, and ascitic components (Aryan et al., 2020). So it is recommended to measure the volume of cystic ovarian neoplasms with a tendency to malignancy using the active contour Laplacian of Gaussian (LoG) volume measurement technique because it has higher sensitivity, utilizing the reliability of edge detection to measure each slice containing clinical information following the shape and size according to surface conditions and the shape. On the other hand, with the subject of cystic ovarian neoplasms, the measurement results are not extreme differences between linear measurement techniques and active contour Laplacian of Gaussian (LoG), cystic ovarian neoplasms are non-malignant, have a flat surface, are only cystic, do not contain various compartments so they can use manual techniques linear measurements.

CONCLUSION

The results of the Wilcoxon non-parametric statistical test on the measurement and calculation of cystic ovarian neoplasms using the linear measurement technique compared with the active contour Laplacian of Gaussian (LoG) segmentation technique obtained a p-value <0.05, show that there is a significant difference between the measurement results and calculation of cystic ovarian neoplasms using linear measurement techniques compared with active contour Laplacian of Gaussian (LoG) segmentation techniques.

The active contour Laplacian of Gaussian (LoG) technique is better in providing measurement and calculation results for cystic ovarian neoplasms as indicated by the higher mean rank value of the Wilcoxon test, namely 17.50. Better measurement results are shown by a higher mean rank value, namely in the active contour Laplacian of Gaussian (LoG) measurement compared to linear measurement. The application of the active contour Laplacian of Gaussian (LoG) technique is superior in identifying neoplasms with a tendency to malignancy which have irregular (uneven) edge characteristics because the segmentation measurement process must be carried out on each slice containing the clinical area of cystic ovarian neoplasm so that the volume and volume can be obtained 3D visualization. Meanwhile, linear measurement can be used on neoplasms with non-aggressive cystic characteristics, having regularly shaped walls with a flat surface, this technique has a level of ease and time efficiency in the process because it has few and simple steps compared to the active Laplacian contour of Gaussian (LoG) measurement technique.

REFERENCES

- Abdulbaqi, H. S., Jafri, M. Z. M., Omar, A. F., Mutter, K. N., Abood, L. K., & Mustafa, I. S. Bin. (2015). Segmentation and estimation of brain tumor volume in computed tomography scan images using hidden Markov random field Expectation Maximization algorithm. *2015 IEEE Student Conference on Research and Development, SCORED 2015*, 8(3), 55–60. <https://doi.org/10.1109/SCORED.2015.7449396>
- Aryan, H., Rusjdi, D. A., & Karmia, H. R. (2020). *Gambaran CT-Scan Abdomen pada Pasien Tumor Ovarium di RSUP Dr. M. Djamil Padang Tahun 2019-2020*.
- Bangare, S. L., Patil, M., Bangare, P. S. T., & Patil, S. (2015). Implementing Tumor Detection and Area Calculation in MRI Image of Human Brain using Image Processing Techniques. *International Journal of Engineering Research and Applications*, Vol. 5(4)(4), Pp. 60-65.

- Biswas, S., & Hazra, R. (2020). Active contours are driven by modified LoG energy terms and optimized penalty terms for image segmentation. *IET Image Processing*, 14(13), 3095–3104. <https://doi.org/10.1049/iet-ipr.2020.0214>
- Chakraborty, S., Johnson, M. A., Miller, W., Noseworthy, M. D., Seely, J., Dennie, C., Nguyen, E., Torres, C., Cormier, T., Khan, N., Schmidt, M., Sheikh, A., Ashforth, R., Midia, M., & Primio, G. Di. (2017). CAR Standard for Magnetic Resonance Imaging. *Canadian Association of Radiologists*, 1–45.
- Diah Priyawati, Indah Soesanti, I. H. (2015). *Kajian Pustaka Metode Segmentasi Citra Pada Mri Tumor Otak*. 207–215.
- Ding, K., Xiao, L., & Weng, G. (2017). Active contours driven by region-scalable fitting and optimized Laplacian of Gaussian energy for image segmentation. *Signal Processing*, 134(50), 224–233. <https://doi.org/10.1016/j.sigpro.2016.12.021>
- Exhibit, S., Taylor, K., & Constantine, S. (2014). Comparison of prostate volume measurements between different techniques and modalities. *CSM Scientific*, m(September), 1–15.
- Ilunga–Mbuyamba, E., Avina–Cervantes, J. G., Cepeda–Negrete, J., Ibarra–Manzano, M. A., & Chalopin, C. (2017). Automatic selection of localized region-based active contour models using image content analysis applied to brain tumor segmentation. *Computers in Biology and Medicine*, 91, 69–79. <https://doi.org/10.1016/j.combiomed.2017.10.003>
- Jung, H., & Kim, W. (2012). Method of tumor volume evaluation using magnetic resonance imaging for outcome prediction in cervical cancer treated with concurrent chemotherapy and radiotherapy. *Radiation Oncology Journal*, 30(2), 70–77. <https://doi.org/10.3857/roj.2012.30.2.70>
- Kadar, N., & Amaliyyah, R. (2021). *Laporan Akhir Profesi Ners Asuhan Keperawatan Perioperatif Pada Ny. N Dengan Diagnosis Medis Neoplasma Ovarium Kistik Suspek Ganas Tindakan Konservatif Surgical Staging (Salpingo-Oofarektomi Bilateral Dan Omentektomi) Di Ruang Central Operating Theatre. February*, 6.
- Khoiria, N., Indriati, D. W., Sundari, A. S., & Diyantoro. (2020). Prevalence and Associated Factors of Ovarian Malignancy : A Cross-sectional Based Study in Surabaya. *Mal J Med Health Sci*, 16(8), 29–34.
- Kurniasari, A., Fahmi, M. N., & Anggorowati, N. (2019). Perbedaan Kadar Interferon Gamma Cairan Asites Pada Subtipe Histopatologi Serosa dan Non-Serosa Kanker Ovarium Tipe Epitel. *Jurnal Kesehatan Reproduksi*, 6(2), 66. <https://doi.org/10.22146/jkr.44182>
- Putri, M. N., Katili, I., Hariri, A., Budiarti, T. A., & Wibowo, G. M. (2021). Perbandingan Pengukuran Volume Tumor Brain MRI Menggunakan Teknik Manual Dan Metode Active Contour. *Jurnal Imejing Diagnostik (JImeD)*, 7(2), 94–97. <https://doi.org/10.31983/jimed.v7i2.7474>
- Roy, S., & Bandyopadhyay, S. K. (2012). Detection and Quantification of Brain Tumor from MRI of Brain and its Symmetric Analysis. *International Journal of Information and Communication Technology Research*, 2(6).
- Soebagjo D, H. (Departemen I. K. M. F. K. U. A. (2017). Onkologi Mata. In *Journal of Chemical Information and Modeling* (Vol. 53, Issue 9).
- Sreenivasan, S., Madhugiri, V., Sasidharan, G., & Kumar, R. V. R. (2016). Measuring glioma volumes: A comparison of linear measurement-based formulae with the manual image

- segmentation technique. *Journal of Cancer Research and Therapeutics*, 12(1), 161–168. <https://doi.org/10.4103/0973-1482.153999>
- Syakrani, N., Widhiyasana, Y., & Efendi, A. A. (2018). Deteksi Tumor Hati dengan Graph Cut dan Taksiran Volume Tumornya. *Jurnal Nasional Teknik Elektro Dan Teknologi Informasi (JNTETI)*, 7(1). <https://doi.org/10.22146/jnteti.v7i1.398>
- Tanjung, R. M. (2021). Implementasi Metode Marker Controlled Watershed Untuk Identifikasi Area Kista Ovarium Pada Citra CT-Scan. *Pelita Informatika: Informasi Dan Informatika*, 10(2), 78–84.
- Wardiyah, A., Aryanti, L., Khoirudin, P., Ade Dea, M., & penulis, K. (2022). Penyuluhan kesehatan tentang pentingnya menjaga kesehatan alat reproduksi. *JOURNAL OF Public Health Concerns*, 2(1), 41–53.
- Westbrook, C., & Talbot, J. (2019). *MRI in Practice* (Vol. 5, Issue 1).
- Yashinta Aqmalia. (2018). *Hubungan Faktor Risiko Umur Dengan Angka Kejadian Kista Adenoma Ovarium di Rumah Sakit Umum Haji Medan Provinsi Sumatera Utara Tahun 2014-2016*. 1–47.